

Long-Term Changes of Functional MRI–Based Brain Function, Behavioral Status, and Histopathology After Transient Focal Cerebral Ischemia in Rats

Kenneth M. Sicard, PhD; Nils Henninger, MD; Marc Fisher, MD;
Timothy Q. Duong, PhD; Craig F. Ferris, PhD

Background and Purpose—The relation between recovery of brain function and neurological status after clinical and experimental cerebral ischemia is incompletely characterized. We assessed the evolution of ischemic injury, behavioral status, and brain activity at acute to chronic periods after transient middle cerebral artery occlusion (tMCAO) in rats.

Methods—Male Sprague-Dawley rats were subjected to 20-minute tMCAO (n=10) or sham operation (n=10). Sensorimotor behavioral testing and multimodal (diffusion, perfusion, T2, and functional) MRI, as well as postmortem hematoxylin-eosin staining, were performed before and up to 21 days after tMCAO. MRI and histological parameters were evaluated in 5 regions of interest within the sensorimotor network. Diffusion, perfusion, and T2 lesion volumes were calculated according to previously established viability thresholds.

Results—Diffusion and perfusion lesions were present during occlusion but disappeared completely and permanently within 30 minutes after reperfusion, with no T2 lesions seen. Functional MRI and behavioral deficits did not normalize until 1 and 21 days after tMCAO, respectively. Histology demonstrated selective neuronal cell death at 7 and 21 days after reperfusion.

Conclusions—Twenty-minute tMCAO produced distinct changes on multimodal MRI, histology, and behavioral parameters acutely and chronically. Normal findings on MRI after transient ischemia may not indicate normal tissue status, as behavioral and histological anomalies remain. Behavioral dysfunction persisting long after the recovery of MRI parameters may relate to the subtle neuronal damage seen on histology. Together, these results may help explain unremitting neurological deficits in stroke or transient ischemic attack patients with normal MRI findings. (*Stroke*. 2006;37:2593-2600.)

Key Words: cerebral blood flow ■ magnetic resonance imaging, diffusion-weighted ■ magnetic resonance imaging, functional ■ magnetic resonance imaging, perfusion-weighted ■ middle cerebral artery occlusion

Sensorimotor neurological deficits are common sequelae of transient cerebral ischemia and typically resolve, though at times incompletely.¹ These impairments have been linked to the presence of postischemic lesions on diffusion-weighted (DWI) and T2-weighted (T2WI) MRI, and neurological recovery has been accompanied by changes in brain activation patterns on functional MRI (fMRI) found to follow clinical and experimental stroke.² However, a clear causal relation between the two remains unestablished, as neurological deficits are frequently found in the absence of detectable lesions on neuroimaging and persist despite evidence of significant structural and functional plasticity changes in the brain.² Such discrepancies may result from the fact that most prior studies failed to use techniques sufficiently sensitive to detect potentially subtle postischemic tissue injury, used

behavioral tests that do not inform exclusively on the affected or examined brain regions, and/or focused largely on acute postischemic time points.^{3–5} A stronger relation between restoration of brain activity and behavioral function may be found when neural and functional measures are matched more specifically and over a wider range of time, because it has been shown that clinical syndromes and brain pathology vary in patients, depending on the location of cerebral infarction and time after the insult.^{2,4,5}

In a recent study, we sought to address the aforementioned concerns by serially tracking regional changes in the spatio-temporal evolution of DWI, perfusion-weighted (PWI), T2WI, and fMRI tissue signatures within the sensorimotor network acutely up to 24 hours after transient middle cerebral artery occlusion (tMCAO) in the rat and correlating these

Received May 11, 2006; final revision received July 1, 2006; accepted July 14, 2006.

From the Center for Comparative Neuroimaging (K.M.S., C.F.F.), Department of Psychiatry, and the Department of Neurology (N.H., M.F.), University of Massachusetts Medical School, Worcester, Mass, and the Yerkes Imaging Center (T.Q.D.), Department of Neurology, Emory University, Atlanta, Ga.

Correspondence to Kenneth M. Sicard, Center for Comparative Neuroimaging (CCNI), University of Massachusetts Medical School, 303 Belmont St, Worcester, MA 01604. E-mail kenneth.sicard@umassmed.edu

© 2006 American Heart Association, Inc.

Stroke is available at <http://www.strokeaha.org>

DOI: 10.1161/01.STR.0000239667.15532.c1

with appropriately specific sensorimotor behavioral measures.³ Most interestingly, fMRI-based brain activity remained significantly perturbed in regions appearing normal on DWI, PWI, and T2WI, and behavioral deficits persisted 1 day after tMCAO, despite complete renormalization of all MRI parameters. However, a significant correlation between changes in brain function and behavior was not found, which could have been attributable to the presence of subtle postischemic histological damage undetectable via the used MRI sequences and/or more chronic changes in brain function that occurred after the experimental end point. To shed light on these issues, the present study investigated long-term evolution of fMRI-based brain function, behavioral status, and histopathology after brief tMCAO.

The major aims of this study were to (1) evaluate the spatiotemporal evolution of pathological and functional alterations within the brain by multimodal MRI and histology, (2) determine the severity and duration of neurological impairments by a battery of sensorimotor behavioral tests, and (3) correlate MRI tissue signatures derived from specific anatomic regions of interest (ROIs) within the sensorimotor network to behavioral and histological outcomes chronically up to 21 days after tMCAO in the rat. It was hypothesized that tMCAO would (1) produce ipsilesional anomalies on DWI, PWI, and fMRI that would fully recover by 1 day after reperfusion, (2) cause contralesional sensorimotor neurological deficits, and (3) generate ipsilesional histological damage possibly accounting for the chronic persistence of behavioral dysfunction.

Materials and Methods

Animal Preparation

All procedures were in accordance with institutional guidelines. Twenty male Sprague-Dawley rats (Taconic Farms; Hudson, NY) weighing 300 to 350 g were divided into groups 1 (n=10) and 2 (n=10) undergoing intraluminal suture 20-minute tMCAO with reperfusion or sham operation, respectively, followed immediately by imaging.³ In sham operation, the suture was inserted 10 mm above the carotid bifurcation without occlusion of the intracerebral vessels.⁶ Anesthesia was induced with 5.0% isoflurane under spontaneous respiration and maintained at 2.0% during surgery and 1.0% during MRI.³ Needle electrodes were subcutaneously inserted into forepaws for 2-minute bilateral somatosensory stimulation during fMRI according to previously optimized parameters.⁷⁻⁹ Inspired hypercapnic challenges (2 minutes) tested cerebrovascular reactivity and consisted of a premixed gas of 5% CO₂ with 21% O₂ and balance N₂.^{9,10} Physiological parameters (respiration rate, heart rate, arterial oxyhemoglobin saturation, and end-tidal CO₂) were noninvasively recorded throughout imaging.⁹ Temperature was maintained at 37.0±0.5°C with a feedback-controlled heating pad.⁹

MRI Measurements

MRI was performed with a 4.7-T/40-cm horizontal magnet with a Biospec Bruker console and a 20 G/cm gradient insert (internal diameter, 12 cm; rise time, 120 μs). A surface coil (internal diameter, 2.3 cm) was used for brain imaging and an actively decoupled neck coil for perfusion labeling.³ Animals were imaged before and during occlusion, as well as at 30 to 180 minutes and 1, 7, and 21 days after reperfusion. An imaging block lasted 30 minutes, recording 3 apparent diffusion coefficient (ADC) maps separately acquired with diffusion-sensitive, single shot, gradient-echo, echoplanar imaging gradients applied along the x, y, or z direction; 2 T2WIs acquired with a fast spin-echo pulse sequence; 4 fMRI scans (2 each of CO₂ and forepaw stimulation tests) where cerebral blood flow (CBF) and

the blood oxygenation level-dependent (BOLD) signal were simultaneously measured by continuous arterial spin-labeling with single-shot, gradient-echo, echoplanar imaging. All scans collected seven 1.5-mm-thick slices according to previously standardized imaging parameters.^{3,9,10} Basal CBF and ADC were the only imaging parameters recorded during occlusion owing to time limitations, and T2WIs were acquired at all time points except 30 minutes after reperfusion.

MRI Data Analysis

Images were analyzed with Matlab software (MathWorks Inc) and STIMULATE (University of Minnesota, Minneapolis)⁹ and coregistered with in-house software.⁷ Quantitative average ADC, CBF, and T2WI maps and their corresponding threshold-derived lesion volumes were calculated.^{2,3,6} Thresholds used to derive ADC, CBF, and T2WI lesion volumes were derived previously and were 0.53×10⁻³ mm²/s, 0.35 mL·g⁻¹·min⁻¹, and +2 SD of T2 values in corresponding contralesional (left) hemispheric tissue, respectively.^{2,11} Cerebral swelling (in mm³) was calculated by subtracting the volume of the contralesional hemisphere from the volume of the ipsilesional hemisphere for slices on T2WI at preocclusion, 180-minute, and 1-, 7-, and 21-day time points. Cross-correlation analysis was performed on fMRI data to calculate activation maps for quantification of CBF and BOLD changes in response to hypercapnia (ΔBOLD_{CO₂} and ΔCBF_{CO₂}) and forepaw stimulation (ΔBOLD_{FS} and ΔCBF_{FS}).⁷⁻⁹

ROI Analysis

Five ROIs were positioned bilaterally on the MRI maps encompassing the following sensorimotor network structures within the MCA territory: forepaw region of primary somatosensory cortex (Sf1), secondary somatosensory cortex (S2), primary motor cortex (M1), ventral thalamus (thalamus), and caudatoputamen (CPU).³ To ensure correct placement and to minimize partial-volume effects,^{7,9,10} ROIs were drawn carefully and conservatively with reference to anatomic images and a stereotaxic rat brain atlas.¹² This approach was used to measure regional ADC, CBF, ΔBOLD_{CO₂}, ΔCBF_{CO₂}, ΔBOLD_{FS}, and ΔCBF_{FS} values, with the lattermost 2 parameters investigated solely within Sf1.^{3,7,9}

Neurological and Histological Evaluation

Adhesive removal, forepaw placement, and general neurological status (Bederson) tests were performed before and at 5 hours and 1, 7, and 21 days postoperatively as described elsewhere.^{3,4} In brief, the adhesive removal test assessed contralesional neglect and ipsilesional bias by recording latency to contact and remove labels (in seconds) as well as the order of label contact (total number of times left and right forepaws were contacted first) and removal (total number of times left and right adhesive labels were removed first). The forepaw placement test examined sensorimotor integration scored as 0 if the placing response was immediate and normal, 1 if the response was delayed, and 2 if the response did not occur within 2 seconds.

At 1 (n=3), 7 (n=3), or 21 days (n=4) after tMCAO subsequent to MRI and behavioral testing, animals were anesthetized and transcardially perfused with 250 mL of heparinized saline, followed by 250 mL of phosphate-buffered 4% paraformaldehyde.⁶ The brain was removed and underwent overnight fixation at 4°C in the same paraformaldehyde solution.⁶ The following day, brains were sectioned coronally into seven 1.5-mm-thick coronal slices corresponding to the MR slices and embedded in paraffin. One 15-μm-thick section from each of the second-, third-, and fourth-most anterior slices was stained with hematoxylin-eosin for microscopic (×100) counting and classification of neurons (ie, intact, necrotic, or apoptotic) in 5 nonoverlapping fields in each ROI, which were performed by an individual (N.H.) blinded to the imaging data.^{6,13} In brief, neurons were classified as necrotic when they exhibited pyknosis, karyorrhexis, karyolysis, cytoplasmic eosinophilia ("red neuron"), or loss of affinity for hematoxylin ("ghost neuron").⁶ Apoptotic neurons were identified by the criteria of Li et al,¹³ ie, by the presence of membrane-bound apoptotic bodies of roughly round

or ovoid shape. At each time point, the total number of neurons was recorded, and the numbers of apoptotic and necrotic neurons within an ROI were summed to derive the number of nonintact neurons; this was done for each ROI.

Statistical Analysis

Data are presented as mean \pm SD unless otherwise stated. Statistical comparisons were performed by ANOVA with post hoc Dunn or Tukey test for multiple comparisons and 2-tailed paired or unpaired Student *t* test, where appropriate. Correlation analyses used the Pearson product moment or the Spearman rank order test. $P < 0.05$ was considered significant.

Results

Physiological Measurements

All basal physiological parameters did not significantly differ between groups, time points, or baseline and stimulus intervals of forepaw stimulation and CO₂ challenges ($P > 0.05$), with the exception of respiration rate and end-tidal CO₂ being transiently increased during hypercapnia ($P < 0.05$; data not shown). These results are consistent with those from normal rats under similar experimental conditions.^{3,9} All proceeding data shown herein are exclusive to the tMCAO group.

DWI, PWI, T2WI, and fMRI

The acute evolution of multimodal MRI parameters was similar to that previously reported after 20-minute tMCAO in rats.³ In brief, during occlusion, CBF and ADC lesion volumes (204 ± 32 and 127 ± 19 mm³, respectively) were present in the right MCA territory. The spatiotemporal analyses of perfusion and diffusion parameters are summarized in Figures 1 and 2, respectively. Regional ipsilesional CBF and ADC values were significantly and heterogeneously reduced during tMCAO relative to corresponding preocclusion or contralesional values ($P < 0.05$) and were most severely decreased within subcortical structures such as the CPu and least severely decreased in lateral border zone regions such as Sf1. Perfusion and diffusion abnormalities fully and permanently resolved by 30 minutes after reperfusion. Postreperfusion contralesional ADC and CBF values did not significantly differ from corresponding preocclusion or sham group values ($P > 0.05$). T2WI revealed no postischemic swelling or lesions in either hemisphere (data not shown). In sham-operated rats, there were no significant differences in ADC, CBF, and T2WI values between hemispheres or time points ($P > 0.05$).

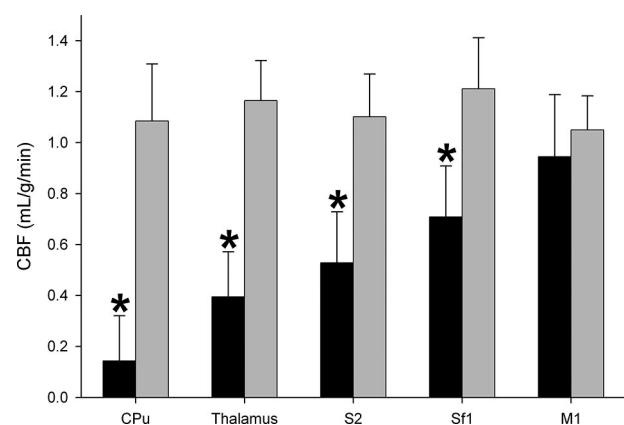


Figure 1. Regional CBF during tMCAO (mean \pm SD). ROIs are ipsilesional (black bars). CBF values did not differ significantly between contralesional ROIs and were averaged (Contra; gray bars). * $P \leq 0.05$ vs Contra.

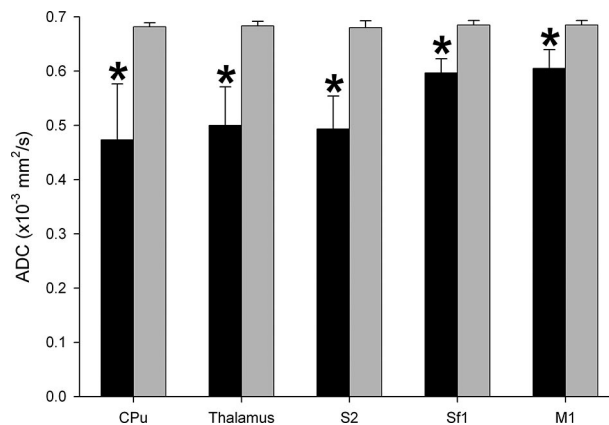


Figure 2. Regional ADC during tMCAO (mean \pm SD). ROIs are ipsilesional (black bars). ADC values did not differ significantly between contralesional ROIs and were averaged (Contra; gray bars). * $P \leq 0.05$ vs Contra.

mic swelling or lesions in either hemisphere (data not shown). In sham-operated rats, there were no significant differences in ADC, CBF, and T2WI values between hemispheres or time points ($P > 0.05$).

Spatiotemporal profiles of hypercapnia and forepaw stimulation-evoked fMRI responses are shown in Figures 3 and 4, respectively. Preocclusion fMRI responses to both tests did not significantly differ between hemispheres ($P > 0.05$). Soon after reperfusion, ipsilesional CO₂ and forepaw stimulation-evoked hemodynamic changes were significantly reduced relative to corresponding unaltered contralesional values ($P < 0.05$) and did not renormalize until 3 and 24 hours after tMCAO, respectively. Lastly, there were no significant differences in the magnitudes of CBF and BOLD responses between hemispheres or time points for both tests in sham animals ($P > 0.05$).

Histopathology

Histological data from tMCAO rats are shown in the Table. No significant postoperative histological abnormalities were demonstrated in the contralesional hemisphere of tMCAO rats or in either hemisphere of sham-operated rats ($P > 0.05$), nor was grossly visible tissue swelling, pallor, and/or cavitation present at any time point. In tMCAO rats, the number of irreversibly damaged neurons within ipsilesional ROIs was not significantly different from those of corresponding contralesional areas 1 day after tMCAO ($P > 0.05$). At 7 and 21 days after reperfusion, a significant number of irreversibly damaged neurons were found in all ipsilesional ROIs ($P < 0.05$), with the exception of Sf1 and M1 at 7 days. Isolated necrotic or apoptotic neurons were surrounded by normally appearing neuropil, glia, and endothelium, suggestive of selective neuronal death (ie, incomplete infarction). Moreover, the severity of these histopathological changes was regionally heterogeneous with, for example, the mean proportion of damaged neurons ranging from $7 \pm 4\%$ in a border zone region, Sf1, to $15 \pm 8\%$ in a core structure, CPu, on day 21.

Behavioral Testing

Figure 5 summarizes behavioral test results of tMCAO rats. tMCAO rats displayed significant postischemic side-specific sensorimotor deficits relative to preocclusion ($P < 0.05$),

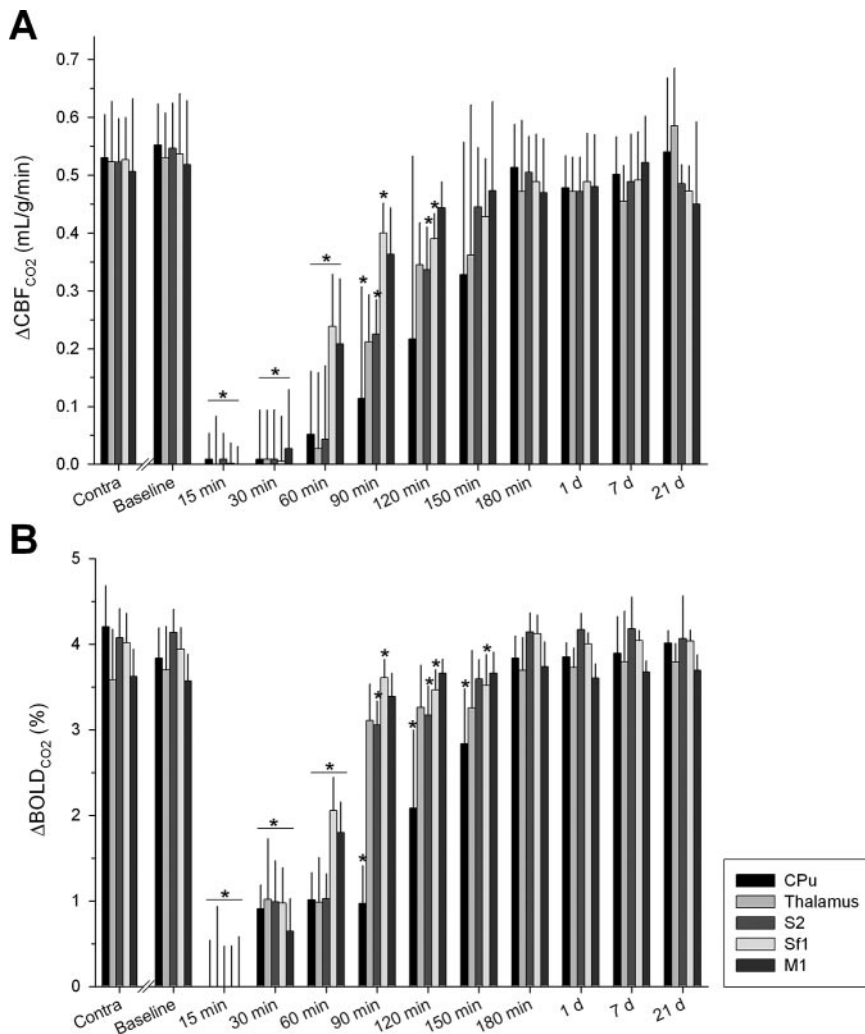


Figure 3. Evolution of regional hypercapnia-evoked (A) $\Delta\text{CBF}_{\text{CO}_2}$ and (B) $\Delta\text{BOLD}_{\text{CO}_2}$ in tMCAO rats (mean \pm SD). ROIs are ipsilesional, and 15-minute to 21-day time points are after reperfusion. Within each contralesional ROI, $\Delta\text{CBF}_{\text{CO}_2}$ and $\Delta\text{BOLD}_{\text{CO}_2}$ values did not differ significantly between time points and were averaged (Contra). Statistical comparisons were made between data within each ROI at each postischemic time point with the equivalent baseline value. $*P \leq 0.05$ vs Contra.

which recovered at 21 days. Specifically, adhesive removal testing revealed increases in latency to contact and remove labels from the contralateral forepaw, indicating contralateral neglect.⁴ This test also showed a lateralization of preference for the order of label contact and removal, further reflecting postischemic contralateral neglect and ipsilateral bias to sensory stimuli.⁴ The forepaw placement test demonstrated preserved ipsilateral function with increased contralateral limb-placing scores. Bederson scoring was normal (score=0) at all time points. In sham rats, there were no significant differences in behavioral parameters between sides and time points ($P > 0.05$). Lastly, no significant correlations were found between behavioral test results and ipsilesional MRI and/or histological parameters at individual time points and when data were grouped (R ranging from -0.46 to 0.82 , $P \geq 0.05$ for all; data not shown).

Discussion

We have previously demonstrated that there is regional variability in the magnitudes of decline and in recovery periods of structural and functional MRI parameters that are not correlated with behavioral status acutely after 20-minute tMCAO in the rat.³ The present study substantially extends those prior findings by evaluating long-term changes on

multimodal imaging and behavioral measures up to 3 weeks after tMCAO. In addition, a thorough histological evaluation of the brain was incorporated. Several important results were found: (1) all imaging modalities recovered fully and permanently by 1 day after reperfusion and did not exhibit secondary abnormalities, (2) permanent reversibility of DWI, PWI, and fMRI anomalies are not predictive of a normal histological or behavioral outcome, and thus, (3) these observations may explain the chronic persistence of neurological deficits in light of a normal MRI battery after transient ischemia.

Postischemic Changes on DWI, PWI, and fMRI

DWI and PWI are widely recognized as powerful tools for rapid detection and evaluation of clinical and experimental cerebral ischemia,^{2,4,8} and fMRI is gaining wide acceptance for assessing postischemic cerebral function and how it relates to neurological recovery.^{2,3} Prior studies indicate that ADC, CBF, and fMRI abnormalities vary regionally in magnitude and are potentially reversible when reperfusion occurs quickly after experimental⁶ or clinical¹⁴ ischemia. The present study extends these findings by combining the aforementioned imaging techniques to examine regional tissue susceptibility within a network of structures with higher spatial resolution and over an extended time period. Together,

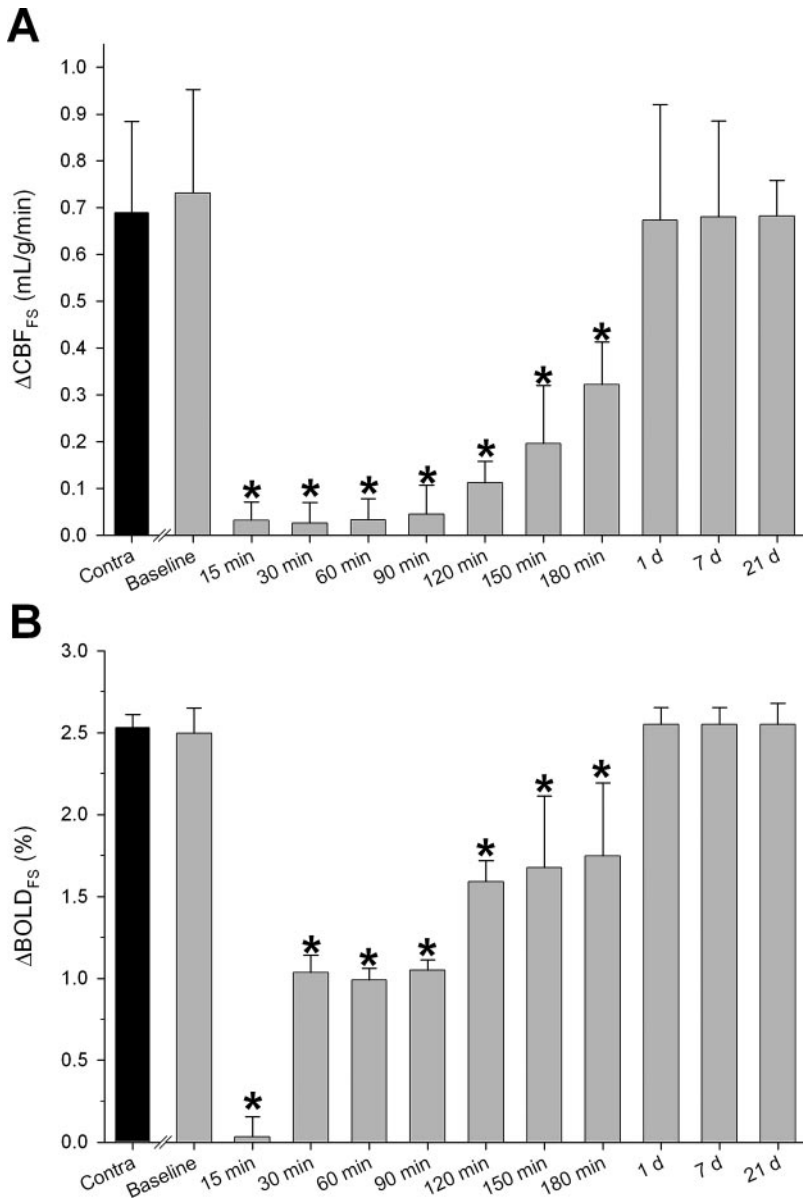


Figure 4. Evolution of regional forepaw stimulation-evoked (A) $\Delta\text{CBF}_{\text{FS}}$ and (B) $\Delta\text{BOLD}_{\text{FS}}$ within ipsilesional (gray bars) and contralesional (Contra; black bar) Sf1 in tMCAO rats (mean \pm SD). Fifteen-minute to 21-day time points are after reperfusion. $\Delta\text{CBF}_{\text{FS}}$ and $\Delta\text{BOLD}_{\text{FS}}$ values did not differ significantly between time points in contralesional Sf1 and were averaged. Statistical comparisons were made between data at each postischemic time point with the equivalent baseline value. * $P \leq 0.05$ vs Contra.

the data show that acute resolution of MR parameters within the sensorimotor network is sustained several weeks after reperfusion and, notably, is unaccompanied by perilesional or hemispheric shift in brain function. Altered brain activation

patterns have been seen in some human and animal stroke studies,² and its absence herein likely reflects differences in postischemic pathological processes owing to interstudy differences in methodology and ischemic duration/severity.^{2,3}

Regional Numbers of Nonintact Neurons in tMCAO and Sham Rats After Reperfusion

Day	Group	Sf1	S2	M1	CPu	Thalamus	Contra
1 (n=3)	MCAO	3 \pm 1 (80 \pm 16)	3 \pm 4 (80 \pm 14)	4 \pm 4 (85 \pm 12)	2 \pm 2 (88 \pm 22)	2 \pm 1 (65 \pm 10)	0 \pm 1 (86 \pm 20)
	Sham	0 \pm 1 (86 \pm 9)	1 \pm 1 (72 \pm 10)	1 \pm 1 (79 \pm 13)	0 \pm 1 (110 \pm 25)	0 \pm 1 (71 \pm 11)	1 \pm 1 (87 \pm 16)
7 (n=3)	MCAO	4 \pm 3 (75 \pm 12)	11 \pm 4* (88 \pm 17)	6 \pm 5 (77 \pm 15)	16 \pm 6* (106 \pm 18)	7 \pm 3* (72 \pm 13)	1 \pm 1 (82 \pm 18)
	Sham	0 \pm 1 (74 \pm 15)	1 \pm 1 (86 \pm 9)	1 \pm 1 (67 \pm 16)	1 \pm 1 (79 \pm 24)	1 \pm 1 (58 \pm 12)	1 \pm 1 (79 \pm 12)
21 (n=4)	MCAO	7 \pm 4* (86 \pm 11)	13 \pm 9* (69 \pm 12)	10 \pm 4* (90 \pm 10)	15 \pm 8* (71 \pm 20)	10 \pm 1* (59 \pm 15)	1 \pm 1 (75 \pm 15)
	Sham	0 \pm 1 (90 \pm 14)	0 \pm 1 (79 \pm 11)	1 \pm 1 (92 \pm 11)	1 \pm 1 (90 \pm 20)	1 \pm 1 (77 \pm 9)	0 \pm 1 (81 \pm 15)

Values are mean \pm SD. ROIs are ipsilesional, times are after tMCAO or sham operation, and percent of nonintact neurons is followed by the total number of neurons counted (in parentheses). Contralesional (Contra) numbers of nonintact neurons did not differ significantly between ROIs or time points for both groups and were averaged. Scattered nonintact neurons constituted a statistically insignificant number of cells in both hemispheres of sham-operated animals as well as the contralesional hemisphere of tMCAO rats and were likely artifacts resulting from removal and histological preparation/fixation of brain tissue.¹³

* $P < 0.05$ vs Contra of respective time point.

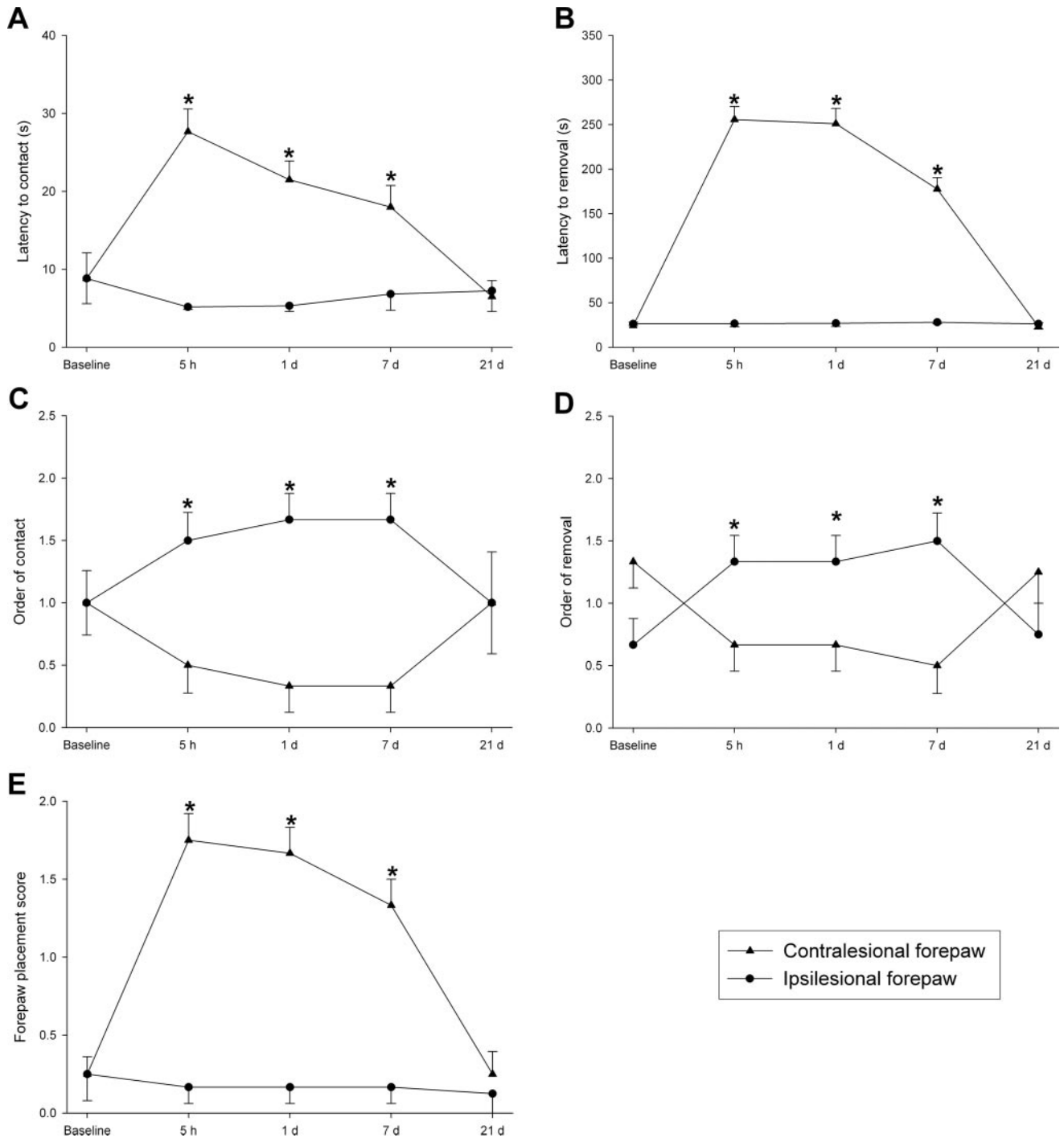


Figure 5. Latency to (A) contact and (B) remove and order to (C) contact and (D) remove adhesive labels, as well as (E) forepaw placement results in tMCAO rats (mean±SEM). Five-hour to 21-day time points are after reperfusion. * $P \leq 0.05$ vs baseline.

Histopathology

The phenomenon of delayed, selective neuronal death was observed after 20-minute occlusion of the MCA. This is consistent with observations made in numerous other species, including humans, that selective neural necrosis requires many days to reach full maturity after transient cerebral ischemia.^{15,16} In this study, neural death within the cerebral sensorimotor network appeared to progressively increase over time. The severity of neuronal injury also appeared to be spatially heterogeneous, which may be attributable to either

regional differences in the severity of ischemia¹⁷ and/or intrinsic regional differences in the rate of maturation of ischemic neural death.¹⁸ Interestingly, although the magnitude of cerebral cell death increased over time, behavioral functions steadily recovered. These 2 processes may be unrelated epiphenomena, in that the dying neurons may have been functionally silenced immediately after insult and therefore uninvolved with subsequent changes in behavior, which instead may have been mediated by concomitant neuroplastic events. Alternately, selective neural death may have contrib-

uted to behavioral recovery if the eliminated cells were functionally inactive. It is known that a normally developing or adapting nervous system is characterized by selective neural death, termed differential degeneration.¹⁹ The elimination of neurons (and their synapses) in this way is thought to fine tune neuronal circuits and may be mediated by genetic instructions, changes within the cytoplasm, adjoining cells, hormones, and the external environment through, eg, sensory experiences.¹⁹ As such, sufficiently selective neuronal turnover after transient cerebral ischemia may represent a form of neuroplasticity associated with improvements in behavioral outcome.²⁰ The functional significance of protracted selective neuronal death after tMCAO remains incompletely understood and should be addressed by future studies.

Selective neuronal cell death was consistently observed in ipsilesional regions where CBF, ADC, T2WI, and fMRI had previously normalized. Accordingly, the normal MRI results found after brief ischemia may be misleading and may fail to detect evolving subtle tissue damage, including neuronal death. Obviously, some changes undetectable by current MRI measurements that lead to neuronal death are initiated after only a few minutes of markedly reduced CBF and cannot be reversed by even rapid reperfusion. This discrepancy between the ability of MRI and histology to detect tissue damage is thought to result from the fact that the former has a significantly lower spatial resolution than the latter.⁶ Indeed, it has been shown that during the acute and subacute stages of cerebral ischemia, selective neuronal cell death does not result in structural changes discernable by either computed tomography or MRI.²¹ Higher spatial resolution or supplementary imaging techniques potentially capable of detecting incomplete infarction—such as positron emission tomography and single-photon emission computed tomography radioligands—may be warranted in the evaluation of cell death after brief ischemic insults.²² Future studies would also be improved by more comprehensive cytological analyses, including examination of a greater number of neuroanatomic structures, stereological cell counting, and examination of additional histological markers of neuronal injury in a larger population of animals.

Behavioral Status

Measuring functional outcome is a relevant and necessary means to assess the consequences of cerebral ischemia.⁴ Many prior studies attempted to show relations between lesion volume and behavioral tests, and although some have found a significant correlation between the two,²³ there remains a major lack of agreement in the literature. This is unsurprising, given that relating total lesion size with behavioral impairment rests on the assumption that the degree or extent of cerebral damage is associated with the behavioral impairment and furthermore, fails to identify specific structures that fulfill the particular behaviors being probed. Taking these perspectives into account—as well as the findings of Gavrilescu and Kase,⁵ which imply that precise behavioral impairments are contingent on the location of ischemic insult—a regional approach seemed more appropriate for investigating relations between brain and behavior. The chosen battery of behavioral tests was sensitive to the effects

of ischemia for the duration of the study, informs exclusively on sensorimotor function, and models the impairments seen in human stroke patients.⁴

The persistent contralateral neglect and ipsilateral bias found herein are consistent with a prior animal study that included similar tests and experimental conditions,⁴ as well as studies in patients recovering from cerebral ischemia,²⁴ but surprisingly, their recovery was not associated with restitution of any contralateral or ipsilateral MRI parameter. Thus, a clear causal relation between changes in MRI and behavior remains to be found and as previously mentioned, may be attributable to an inability of imaging to detect subtle postischemic pathological changes underlying behavioral deficits.⁶ This conclusion is supported by histological analysis demonstrating slight to moderate selective neural cell death within the sensorimotor network. Behavioral recovery plausibly resulted from plastic changes in the brain (eg, axonal/dendritic outgrowth, synaptogenesis, and redundancy in brain circuitry),² which we plan to investigate in a future study with immunohistochemistry.

Clinical Implications

As is the case with all animal studies, the results found herein are unlikely to be wholly transferable to the human condition, and caution must be exercised when attempting to extrapolate them to the clinic. Nonetheless, our findings parallel those of clinical studies on patients with transient ischemic attack (TIA) or minor stroke in several respects. First, small but significant metabolic alterations and impaired cerebrovascular reactivity to hypercapnia have been found in the symptomatic hemisphere of TIA patients with normal imaging^{25,26}—findings consistent with the diminished fMRI responses to somatosensory stimulation and CO₂ challenge reported herein. Second, populations of TIA/minor stroke patients are found to possess neurological, neuropsychological, and physical performance deficits that may endure for days to weeks before resolving, despite normal CBF and fully reversed hyperacute DWI lesions.^{1,27–29} Last, indirect evidence of incomplete infarction has been discovered days to weeks after transient ischemic episodes characterized by no neuroimaging abnormalities,³⁰ which is similar to the results of this study, although we are unaware of any published study incorporating histopathological analysis of human brain tissue after TIA for conclusive detection of incomplete infarction.

The preceding parallels provide clinicians with at least 2 pieces of important information. First, the data seem to show that the diagnostic utility of diffusion/perfusion MRI after brief ischemia may be compromised by short passages of time. Second, the data argue that normal DWI, PWI, T2WI, and fMRI after transient ischemia may not indicate normal tissue status, as histology and behavior remain abnormal, which may help explain persisting neurological deficits in subsets of patients with transient ischemia and a normal MRI battery.^{27–29} Last, because incomplete infarction and changes in brain metabolism have been shown to have prognostic impact on clinical outcome in TIA patients,³¹ our results suggest that adjunct neuroimaging modalities capable of detecting such events may aid in the development of more effective treatment strategies for this patient population.

Furthermore, our data emphasize that even brief transient ischemia induces neuronal cell death and behavioral impairment that warrant development of treatment strategies beyond reducing risk factors.

Summary

In conclusion, the present study demonstrates that 20-minute tMCAO produces behavioral deficits that continue despite recovery of MRI parameters in corresponding brain regions. These findings may be relevant to a clinical subset of patients with negative MRI results but persistent neurological dysfunction and may increase insight into the functional, pathophysiological, and anatomic aspects of brain injury associated with transient focal cerebral ischemia.

Sources of Funding

This study was supported by the National Institutes of Health (R01 DA013517).

Disclosures

None.

References

- Kernan WN, Viscoli CM, Brass LM, Gill TM, Sarrel PM, Horwitz RI. Decline in physical performance among women with a recent transient ischemic attack or ischemic stroke: opportunities for functional preservation: a report of the Women's Estrogen Stroke Trial. *Stroke*. 2005;36:630–634.
- Dijkhuizen RM, Singhal AB, Mandeville JB, Wu O, Halpern EF, Finklestein SP, Rosen BR, Lo EH. Correlation between brain reorganization, ischemic damage, and neurologic status after transient focal cerebral ischemia in rats: a functional magnetic resonance imaging study. *J Neurosci*. 2003;23:510–517.
- Sicard KM, Henninger N, Fisher M, Duong TQ, Ferris CF. Differential recovery of multimodal MRI and behavior after transient focal cerebral ischemia in rats. *J Cereb Blood Flow Metab*. 2006. In press.
- Virley D, Beech JS, Smart SC, Williams SC, Hodges H, Hunter AJ. A temporal MRI assessment of neuropathology after transient middle cerebral artery occlusion in the rat: correlations with behavior. *J Cereb Blood Flow Metab*. 2000;20:563–582.
- Gavrilescu T, Kase CS. Clinical stroke syndromes: clinical-anatomical correlations. *Cerebrovasc Brain Metab Rev*. 1995;7:218–239.
- Li F, Liu KF, Silva MD, Omae T, Sotak CH, Fenstermacher JD, Fisher M, Hsu CY, Lin W. Transient and permanent resolution of ischemic lesions on diffusion-weighted imaging after brief periods of focal ischemia in rats: correlation with histopathology. *Stroke*. 2000;31:946–954.
- Liu ZM, Schmidt KF, Sicard KM, Duong TQ. Imaging oxygen consumption in forepaw somatosensory stimulation in rats under isoflurane anesthesia. *Magn Reson Med*. 2004;52:277–285.
- Shen Q, Ren H, Cheng H, Fisher M, Duong TQ. Functional, perfusion and diffusion MRI of acute focal ischemic brain injury. *J Cereb Blood Flow Metab*. 2005;25:1265–1279.
- Sicard KM, Duong TQ. Effects of hypoxia, hyperoxia, and hypercapnia on baseline and stimulus-evoked bold, CBF, and CMRO₂ in spontaneously breathing animals. *Neuroimage*. 2005;25:850–858.
- Sicard K, Shen Q, Brevard ME, Sullivan R, Ferris CF, King JA, Duong TQ. Regional cerebral blood flow and BOLD responses in conscious and anesthetized rats under basal and hypercapnic conditions: implications for functional MRI studies. *J Cereb Blood Flow Metab*. 2003;23:472–481.
- Shen Q, Meng X, Fisher M, Sotak CH, Duong TQ. Pixel-by-pixel spatiotemporal progression of focal ischemia derived using quantitative perfusion and diffusion imaging. *J Cereb Blood Flow Metab*. 2003;23:1479–1488.
- Paxinos G, Watson C. *The Rat Brain in Stereotaxic Coordinates*. Boston: Academic Press; 1997.
- Li Y, Powers C, Jiang N, Chopp M. Intact, injured, necrotic and apoptotic cells after focal cerebral ischemia in the rat. *J Neurol Sci*. 1998;156:119–132.
- Kamal AK, Segal AZ, Ulug AM. Quantitative diffusion-weighted MR imaging in transient ischemic attacks. *AJNR Am J Neuroradiol*. 2002;23:1533–1538.
- Kirino T, Tamura A, Sano K. Delayed neuronal death in the rat hippocampus following transient forebrain ischemia. *Acta Neuropathol (Berl)*. 1984;64:139–147.
- Petito CK, Feldmann E, Pulsinelli WA, Plum F. Delayed hippocampal damage in humans following cardiorespiratory arrest. *Neurology*. 1987;37:1281–1286.
- Garcia JH, Mitchem HL, Briggs L, Morawetz R, Hudetz AG, Hazelrigg JB, Halsey JH Jr, Conger KA. Transient focal ischemia in subhuman primates: neuronal injury as a function of local cerebral blood flow. *J Neuropathol Exp Neurol*. 1983;42:44–60.
- Smith ML, Kalimo H, Warner DS, Siesjö BK. Morphological lesions in the brain preceding the development of postischemic seizures. *Acta Neuropathol (Berl)*. 1988;76:253–264.
- Gordon N. Apoptosis (programmed cell death) and other reasons for elimination of neurons and axons. *Brain Dev*. 1995;17:73–77.
- Chambers RA, Potenza MN, Hoffman RE, Miranker W. Simulated apoptosis/neurogenesis regulates learning and memory capabilities of adaptive neural networks. *Neuropsychopharmacology*. 2004;29:747–758.
- Garcia JH, Lassen NA, Weiller C, Sperling B, Nakagawara J. Ischemic stroke and incomplete infarction. *Stroke*. 1996;27:761–765.
- Lahorte CM, Vanderheyden JL, Steinmetz N, Van de Wiele C, Dierckx RA, Slegers G. Apoptosis-detecting radioligands: current state of the art and future perspectives. *Eur J Nucl Med Mol Imaging*. 2004;31:887–919.
- Rogers DC, Campbell CA, Stretton JL, Mackay KB. Correlation between motor impairment and infarct volume after permanent and transient middle cerebral artery occlusion in the rat. *Stroke*. 1997;28:2060–2065; discussion 2066.
- D'Erme P, Robertson I, Bartolomeo P, Daniele A, Gainotti G. Early rightwards orienting of attention on simple reaction time performance in patients with left-sided neglect. *Neuropsychologia*. 1992;30:989–1000.
- Bisschops RH, Kappelle LJ, Mali WP, van der Grond J. Hemodynamic and metabolic changes in transient ischemic attack patients: a magnetic resonance angiography and ¹H-magnetic resonance spectroscopy study performed within 3 days of onset of a transient ischemic attack. *Stroke*. 2002;33:110–115.
- Silvestrini M, Vernieri F, Troisi E, Passarelli F, Matteis M, Pasqualetti P, Rossini PM, Caltagirone C. Cerebrovascular reactivity in carotid artery occlusion: possible implications for surgical management of selected groups of patients. *Acta Neurol Scand*. 1999;99:187–191.
- Inoue N, Sato K, Maruo T, Goto S, Ushio Y. Diffusion weighted image negative transient ischaemic attack and reversible ischaemic neurological deficit: a report of 10 patients with complete recovery. *J Clin Neurosci*. 2004;11:619–622.
- Kidwell CS, Alger JR, Di Salle F, Starkman S, Villablanca P, Bentson J, Saver JL. Diffusion MRI in patients with transient ischemic attacks. *Stroke*. 1999;30:1174–1180.
- Rao R, Jackson S, Howard R. Primitive reflexes in cerebrovascular disease: a community study of older people with stroke and carotid stenosis. *Int J Geriatr Psychiatry*. 1999;14:964–972.
- Vorstrup S, Hemmingsen R, Henriksen L, Lindewald H, Engell HC, Lassen NA. Regional cerebral blood flow in patients with transient ischemic attacks studied by xenon-133 inhalation and emission tomography. *Stroke*. 1983;14:903–910.
- Baumgartner C, Zeiler K, Kollegger H, Lind C, Oder W, Deecke L. Prognosis after transient ischemic attacks. *Versicherungsmedizin*. 1991;43:75–79.